



PATIENT

Chiquis Andrade

PRESENTING CLINICAL SIGNS

History: Grade II/VI heart murmur. No clinical signs.

SPECIES

Canine

ECHOCARDIOGRAM FINDINGS

2D, m-mode, color flow and Doppler imaging is available.

Left ventricle: The LV diameter is increased with increased sphericity. Adequate myocardial function with evidence of volume overload. LV wall thicknesses are normal.

BREED

Maltese

Left atrium: The left atrium is mild to moderately dilated

Mitral valve: The mitral valve is normal with no mitral regurgitation.

SEX

Female Intact

Aortic valve/Aorta: The aortic valve is normal in morphology and mobility. Mildly elevated aortic outflow velocity; laminar flow. No aortic insufficiency.

Right ventricle: Normal right ventricular diameter and morphology indicating no overt evidence of pulmonary arterial hypertension.

Right atrium: Normal RA dimension.

Tricuspid valve: The tricuspid valve appears normal with no tricuspid regurgitation.

AGE

3.5 years

Pulmonic valve/Pulmonary artery: The MPA is significantly dilated. The pulmonic valve is normal in morphology and mobility. No pulmonic insufficiency. Normal RVOT velocity; laminar flow. Continuous flow detected with color Doppler in the distal pulmonary artery in the region of the ductus arteriosus. A PDA is visualized on 2D imaging. High velocity shunt; L-R (4.9m/s). No PI.

WEIGHT

9.13lbs

Pericardium/other: No pericardial or pleural effusion noted. No obvious cardiac masses.

Heart rhythm: ECG reveals a sinus rhythm with an average HR of 100bpm.

INTERPRETED BY

Maggie Machen
Lamy, DVM
DACVIM (Cardiology)

2-Dimensional Measurements

Ao diam (cm)	1.4
LA diam (cm)	2.1
LA:Ao (Swe)	1.5
IVS thickness (cm)	0.6
LVID diastole (cm)	3.0
PW thickness (cm)	0.6
LVID systole (cm)	1.6
FS (%)	49

Doppler Measurements

PV Vmax (m/s)	1.0
AoV Vmax (m/s)	1.8
MR Vmax (m/s)	NA
TR Vmax (m/s)	NA
TR PG (mmHg)	NA

IMAGING

PERFORMED BY

Eduardo Rodriguez
III, RCS

INTERPRETATION OF THE FINDINGS

The cause of the murmur is a patent ductus arteriosus (PDA). This is a congenital condition where a blood vessel present in the fetus remains open after birth. When patent, this allows blood to recirculate through the lungs inappropriately and volume overloads the left heart chambers as is seen here. No additional issues are seen. The LA is mild to moderately dilated indicating relatively low risk for imminent complication; however, this may progress in the future.

HOSPITAL NAME

East Boston Animal
Hospital

If left open, this condition will likely shorten lifespan, with risk for progression to CHF in the future. Even without symptoms, cardiac support with Pimobendan is recommended regardless of if surgical closure is an option as below. Gold standard therapy includes medical support and referral for surgical closure of the vessel. This can be done interventionally or through a thoracotomy, and consultation with a local Cardiologist is recommended. In a 9lb dog, a thoracotomy may be necessary. Success rates for the procedure are generally high and will help give the best prognosis possible.

REFERRING VET

Dr. Chopra

INVOICE

30637

DATE

5/5/23



PATIENT

Chiquis Andrade

Going forward the patient will be at risk for progression to CHF, development of arrhythmias, PDA reversal due to development of pulmonary hypertension, exertional syncope, and/or sudden death at home.

SPECIES

Canine

BREED

Maltese

SEX

Female Intact

AGE

3.5 years

WEIGHT

9.13lbs

INTERPRETED BY

Maggie Machen Lamy, DVM
 DACVIM (Cardiology)

IMAGING PERFORMED BY

Eduardo Rodriguez III, RCS

HOSPITAL NAME

East Boston Animal Hospital

REFERRING VET

Dr. Chopra

INVOICE

30637

DATE

5/5/23

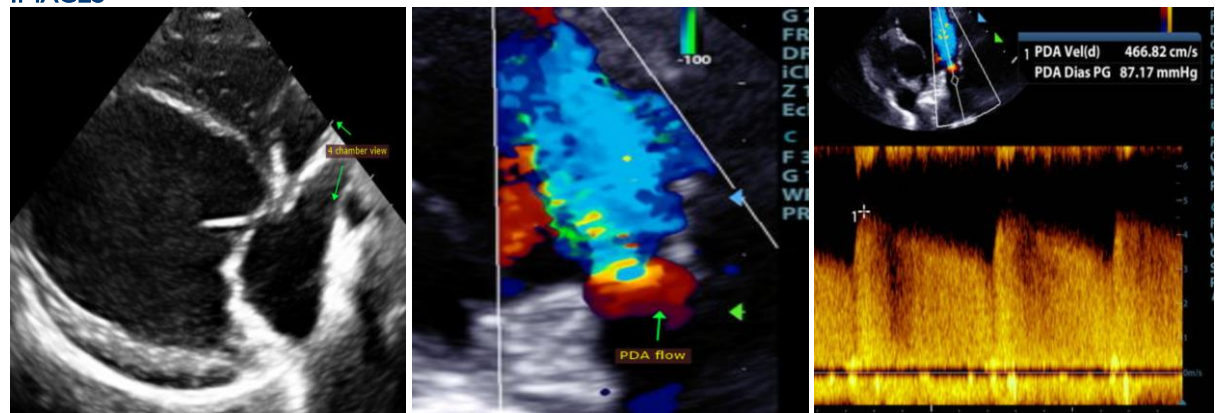
RECOMMENDATIONS

- Institute Pimobendan 0.2-0.3mg/kg PO q12h.
- Referral for surgical consultation ASAP.
- Omega fatty acid supplementation and mild salt restriction may be of some long-term benefit.
- Mild activity restriction is advised.
- Monitor for development of a cough, labored breathing, exercise intolerance or collapse episodes.

PLAN

- If surgery is not an option, recommend recheck exam and echocardiogram in 6 months to screen for progression and need for additional medications, sooner if clinical signs arise (progressive cough, labored breathing, syncope, etc.).
- If surgical closure is performed, recheck as dictated by the surgical report (typically 2-3 months following closure to determine if medication can be discontinued).

IMAGES



The information and recommendations provided are based on the images presented by the referring veterinarian. No evaluation can be communicated regarding pathology that was not visible in the image/video clips provided.

Thank you for this referral. This report was generated using transcription software, and minor dictation errors may be present. If the clinical or image interpretation does not parallel your findings or if I can be of any further assistance, please contact me.

Maggie Machen Lamy, DVM
 Diplomate of the American College of Veterinary Internal Medicine (Cardiology)
 info@sonopath.com

Echocardiogram performed by: Pamela Harrigan, RDCS
 Pet Animal Ultrasound Service (4paus.com)